BDS Year 4 Regular batch

Academic Year 2023-2024

Subject: Oral Medicine

Topic: RED AND WHITE LESIONS- Part III

Dr. Akansha Budakoti

S.Lecturer

Dept. of Oral Medicine and Radiology

Proliferative verrucous leukoplakia

Introduction

- Proliferative verrucous leukoplakia (PVL) was first described by Hansen et al in 1985.
- PVL is recognized as a particularly aggressive form of oral leukoplakia.
- It has considerable morbidity and a strong potential for malignant transformation.

Etiology

- Many potential etiologies have been hypothesized, but little has been proved about the origin of this disease process.
- The disease seems to be **idiopathic**.
- **Tobacco** is frequently absent as a known risk factor as OPVL occurs both in smokers and non-smokers.
- An association has been reported between **human papillomavirus** (HPV) and OPVL, especially for HPV **types 16 and 18**.
- It has also been reported in association with **Epstein-Barr virus** or **candida** infection.
- Despite such extensive works, the etiology of OPVL is still as enigmatic as the disease itself.

SUMANDEEP VIDYAPEETH
K M SHAH DENTAL COLLEGE AND HOSPITAL

Clinical features

- Age : The mean age at the time of diagnosis is slightly over 60 years.
- F : M = 4:1
- Predilection for this lesion in elderly women
- It has been shown that almost all lesions occur bilaterally, mainly affecting the lower alveolar ridge and buccal mucosa.
- Clinically, it generally presents as a simple benign form, which tends to spread and become diffuse.
- In time, OPVL develops exophytic, wart-like or erythroplakic areas that become oral carcinomas.

SUMANDEEP VIDYAPEETH
K M SHAH DENTAL COLLEGE AND HOSPITAL

PVL on Alveolar ridge

SUMANDEEP VIDYAPEETH
K M SHAH DENTAL COLLEGE AND HOSPITAL

PVL on BUCCAL MUCOSA

SUMANDEEP VIDYAPEETH
K M SHAH DENTAL COLLEGE AND HOSPITAL

PVL on Gingiva

SUMANDEEP VIDYAPEETH
K M SHAH DENTAL COLLEGE AND HOSPITAL

PVL on labial mucosa

SUMANDEEP VIDYAPEETH
K M SHAH DENTAL COLLEGE AND HOSPITAL

Diagnosis

- Because of the lack of specific histological criteria, the diagnosis of OPVL is based on combined clinical and histopathologic evidence of progression.

- There are few studies that apply a set of diagnostic criteria that are mentioned as follows:

SUMANDEEP VIDYAPEETH
K M SHAH DENTAL COLLEGE AND HOSPITAL

Table 1. Proposal of major and minor diagnostic criteria for PVL recommended by Cerero-Lapiedra et al. (2010).

	Major criteria (MC)		Minor criteria (mc)
A	A leukoplakia lesion with more than two different oral sites, which is most frequently found in the gingiva, alveolar processes and palate.	**a**	An oral leukoplakia lesion that occupies at least 3 cm when adding all the affected areas.
B	The existence of a verrucous area.	**b**	That the patient be female.
C	That the lesions have spread or engrossed during development of the disease.	**c**	That the patient (male or female) be a non-smoker.
D	That there has been a recurrence in a previously treated area.	**d**	A disease evolution higher than 5 years.
E	Histopathologically, there can be from simple epithelial hyperkeratosis to verrucous hyperplasia, verrucous carcinoma or oral squamous cell carcinoma, whether in situ or infiltrating.		

- **In order to make the diagnosis of PVL, it was suggested that one of the two following combinations of the criteria mentioned before were met.**
  1. **Three major criteria (E being among them) or**
  2. **Two major criteria (E being among them) + two minor criteria.**

- **Nevertheless, at present, there is no criterion that will allow for the early diagnosis of the disease.**

Evidence

Authors	Pentenero M(1), Meleti M, Vescovi P, Gandolfo S
Title	Oral proliferative verrucous leucoplakia: are there particular features for such an ambiguous entity? A systematic review Grade: ++++
Aim	to collate the available evidence on the following issues for PVL: patient demographics, aetiology, lesion location(s), malignant potential, location and histopathological features of transformed lesions, disease-specific survival rates and treatment response.
Results	20 studies selected indicated that PVL does not seem to be correlated with the major risk factors of oral carcinoma. It affects mainly elderly women and has a very high malignant transformation rate, particular site distribution and histopathological features of transformed lesions.
Interpertation	The present results demonstrate that PVL has particular features.

Br J Dermatol. 2014;170(5):1039-47.

Treatment

- Advise patients with OPVL to avoid other known factors associated with development of oral carcinoma, such as tobacco, alcohol and betel.

SUMANDEEP VIDYAPEETH
K M SHAH DENTAL COLLEGE AND HOSPITAL

Medical Care

- Managements used for traditional leukoplakia have been disappointing.

- Carbon dioxide laser, radiation, topical bleomycin solution, oral retinoids, beta-carotene and systemic chemotherapy have **all failed** at achieving permanent cure.

- **Methisoprinol** is a synthetic agent capable of inhibiting viral ribonucleic acid synthesis and replication and of stimulating antiviral cell–mediated reactions that has been shown to have some clinical efficacy in HPV-induced lesions.

SUMANDEEP VIDYAPEETH
K M SHAH DENTAL COLLEGE AND HOSPITAL

- **Laser ablation reportedly has been successful in a very small group of patients followed for 6-18 months.**

- **However, multiple treatments over the course of the disease progression may be required.**

Surgical Care

- This lesion is resistant to the presently available treatment modalities.

- Therefore, total excision with free surgical margins is critical combined with a lifelong follow-up.

SUMANDEEP VIDYAPEETH
K M SHAH DENTAL COLLEGE AND HOSPITAL

Malignant transformation and recurrences

- OPVL is known for its aggressive pathology
- It has multifocal involvement, high malignant transformation rates (60-100%), frequent recurrences (87-100%) and high mortality rates (30-50%).
- The gingiva and palate represented the areas with the highest frequency of these multiple malignant tumors.
- Given the high tendency for OSCCs to appear in these patients, they should be checked for life at least once every 6 months.

SUMANDEEP VIDYAPEETH
K M SHAH DENTAL COLLEGE AND HOSPITAL

ORAL LICHEN PLANUS

- **Introduction : It is a common chronic immunologic inflammatory mucocutaneous disorder that varies in appearance from keratotic (reticular or plaque like) to erythematous and ulcerative.**

- **It has malignant potential**

Epidemiology-

- **Prevalence- o.5-2.2%**
- **Women**
- **Mean age- 55yrs**

SUMANDEEP VIDYAPEETH
K M SHAH DENTAL COLLEGE AND HOSPITAL

Etiopathology :

- Exact etiology- unknown
- It involves a cell mediated immunologically induced degeneration of the basal cell layer of the epithelium
- CD8+ T-cell trigger the apoptosis of oral epithelial cells
- These cells cannot discriminate between inherent molecule of body & foreign antigen

SUMANDEEP VIDYAPEETH
K M SHAH DENTAL COLLEGE AND HOSPITAL

- The CD8+ cells may recognize antigen associated with major histocompatibility complex class I on keratinocyte
- Antigen recognition & activation
- CD8+ T cell may trigger keratinocyte apoptosis
- Activated T cell release cytokines
- That attract additional lymphocyte at developing lesion
- Antigen-unknown.
- Cofactors : Stress, Diabetes, Hepatitis C, Trauma and Hypersensitivity to drugs and metals

Types :

- Reticular,
- Papular,
- Plaque,
- Bullous,
- Erythematous,
- Ulcerative

- Different clinical manifestation- due to magnitude of subepithelial inflammation

Reticular form

- Fine white lines or striae (Wickham's striae).
- Show network but can also show annular pattern(interlacing)
- Encountered in all regions of oral mucosa
- Mostly bilaterally on buccal mucosa & rarely mucosal side of lip
- Sometimes- vermilion borders of lip

SUMANDEEP VIDYAPEETH
K M SHAH DENTAL COLLEGE AND HOSPITAL

SUMANDEEP VIDYAPEETH
K M SHAH DENTAL COLLEGE AND HOSPITAL

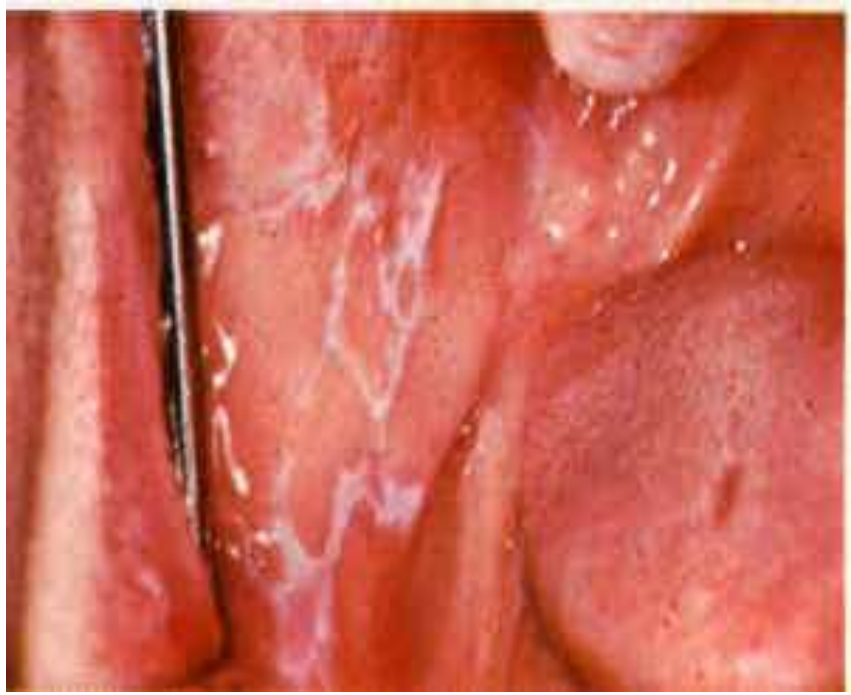

Papular type-

- Usually present in initial phase of the disease
- Characterized by small white dots intermingled with reticular form

Plaque type

- Homogenous well demarcated white plaque- not always surrounded by striae
- Very similar to homogenous oral leukoplakia

- Reticular, papular & plaque like forms- asymptomatic
- Pt. may experience feeling of roughness

SUMANDEEP VIDYAPEETH
K M SHAH DENTAL COLLEGE AND HOSPITAL

Bullous form-

- Very unusual
- Appear as a bullous structure surrounded by reticular network.

SUMANDEEP VIDYAPEETH
K M SHAH DENTAL COLLEGE AND HOSPITAL

Erythematous (ATROPHIC)

- Characterized by homogenously red area
- Present in buccal mucosa, palate- striae usually seen in periphery
- Sometimes seen over attached gingiva- present as a desquamative gingivitis

Ulcerative

- Most disabling
- Fibrin coated ulcers surrounded by erythematous zone, with radiating white striae

Clinical manifestation

- Cutaneous lesions- 15% pt. with OLP
- Appear as pruritic erythematous to violaceous papule
- Flat topped
- Discrete or coalesce to form plaque
- Seen over trunk & flexor surface of arm & legs
- Pt. may feel relief following intense scratching but trauma may aggravate the lesions- koebner phenomenon
- Most frequent extraoral mucosal site- genital mucosa
- 20% pt. with OLP- has genital lesion

SUMANDEEP VIDYAPEETH
K M SHAH DENTAL COLLEGE AND HOSPITAL

Symptoms-

- Burning
- Pain
- Vaginal discharge

- OLP associated with esophageal LP- dysphagia

Diagnosis-histopathological examination

- Areas of hyperparakeratosis or hyperorthokeratosis
- With thickening of granular cell layer
- Saw tooth appearance to rete pegs
- Liquefaction degeneration or necrosis of basal cell layer
- Eosinophilic band – just beneath the basement membrane & represent fibrin covering lamina propria
- A dense subepithelial band shaped infiltrate of lymphocyte & macrophages
- Deposition of antibodies & complement can be observed

SUMANDEEP VIDYAPEETH
K M SHAH DENTAL COLLEGE AND HOSPITAL

Direct immunoflourescent studies

- Nearly all specimen react with antifibrinogen

- Intensely positive flourescence that outlines the basement membrane zone with numerous irregular extension into the superficial lamina propria.

SUMANDEEP VIDYAPEETH
K M SHAH DENTAL COLLEGE AND HOSPITAL

Differential diagnosis

Reticular type-

- Lichenoid contact reaction- on buccal mucosa & lat. Border of tongue
- Oral lichenoid drug reaction- history
- GVHD- more generalised, xerostomia, localised skin involvement, liver dysfunction
- Discoid lupus erythematosus - striae more prominent, more marked hyperkeratinization, striae may terminate against sharp demarcation

SUMANDEEP VIDYAPEETH
K M SHAH DENTAL COLLEGE AND HOSPITAL

- **Plaque like- homogenous oral leukoplakia**
- **Erythematous- mucous membrane pemphigoid- nikolsky's sign**
- **Ulcerative- erythema multiforme**

  adverse reaction to NSAID's

Treatment :

First line of therapy-

Topical steroids - very potent clobetasol propionate(clovate)

triamcinolone acetonide (kenacort)

Mouth rinse & gel- 2-3 times for 3 wks followed by tapering for 9 weeks

Second line of therapy-

Cyclosporin- (imusporin) (temporary burning sensation)

Tacrolims- 0.1% ointment (tacroz- glenmar)- (increased risk of malignancy)

Retinoids

- **Systemic corticosteroids- in recalcitrant cases**

  1mg/kg daily for 7 days followed by reduction of 10 mg each subsequent days

In erythematous OLP-

- **Oral hygiene should be optimized before starting steroids**
- **For gingival involvement - Steroid gel in prefabricated plastic trays – used for 30 min. at each application**

Evidence

Authors	Lodi G, Carrozzo M, Furness S, Thongprasom K.
Title	**Interventions for treating oral lichenplanus: a systematic review.** Grade: ++++
Aim	The aim of this review was to assess the evidence for the efficacy and safety of treatments for symptomatic OLP
Results	A total of 28 trials were included in this Cochrane review. There was no evidence from three RCTs that topical pimecrolimus is better than placebo in reducing pain from OLP. There was weak evidence from two RCTs that topical Aloe Vera may be associated with a reduction in pain compared with placebo. There was weak and unreliable evidence from two small trials, at high risk of bias, that topical cyclosporine may reduce pain and clinical signs of OLP.
Interpretation	From the 28 trials included in this systematic review, the wide range of interventions compared means there is insufficient evidence to support the superior effectiveness of any specific treatment.

Br J Dermatol. 2012 May;166(5):938-47.

SUMANDEEP VIDYAPEETH
K M SHAH DENTAL COLLEGE AND HOSPITAL

Malignant transformation-

- Incidence-0.2% per year
- In some studies plaque like OLP- over represented
- But ulcerated lesions- suspected to be associated with OLP

SUMANDEEP VIDYAPEETH
K M SHAH DENTAL COLLEGE AND HOSPITAL

Lichenoid reactions

- Lichenoid reactions and lichen planus exhibit similar histopathologic features.

- Lichenoid reactions were differentiated from lichen planus on the basis of (1) their association with the administration of a drug, contact with a metal, the use of a food flavoring, or systemic disease and (2) their resolution when the drug or other factor was eliminated or when the disease was treated.

- Clinically, lichenoid lesions may exhibit the classic appearance of lichen planus, but atypical presentations are seen, and some of the dermatologic lesions included in this category show little clinical lichenification.

SUMANDEEP VIDYAPEETH
K M SHAH DENTAL COLLEGE AND HOSPITAL

SUMANDEEP VIDYAPEETH
K M SHAH DENTAL COLLEGE AND HOSPITAL

TABLE 5-4 Drugs and Materials Implicated in Oral Lichenoid Reactions

Category	Drugs or Materials
Antimicrobials	Dapsone Ketoconazole Para-aminosalicylic acid Sodium aminosalicylate Streptomycin Sulfamethoxazole Tetracycline
Antiparasitics	Antimony compounds (s Organic arsenicals Chloroquine Pyrimethamine Quinacrine
Antihypertensives	ACE inhibitors Chlorothiazide Hydrochlorothiazide Labetalol Mercurial diuretics Methyldopa Practolol
Antiarthritics	Aurothioglucose Colloidal gold (Europe only) Gold sodium thiomalate, thiosulfate
Anxiolytics	Lorazepam
NSAIDs	Fenclofenac Ibuprofen Naproxen Phenylbutazone
Oral hypoglycemic agents	Chlorpropamide Tolazamide Tolbutamide
Uricosuric agents	Allopurinol
Miscellaneous drugs	Iodides Penicillamine Quinidine sulfate
Chemicals; dental restorative materials	Substituted paraphenylenediamines used in color film developers; dental casting alloys and amalgam restorations

SUMANDEEP VIDYAPEETH
K M SHAH DENTAL COLLEGE AND HOSPITAL

TABLE 5-4 Drugs and Materials Implicated in Oral Lichenoid Reactions

Category	Drugs or Materials
Antimicrobials	Dapsone Ketoconazole Para-aminosalicylic acid Sodium aminosalicylate Streptomycin Sulfamethoxazole Tetracycline
Antiparasitics	Antimony compounds (stibophen, stibocaptate) Organic arsenicals Chloroquine Pyrimethamine Quinacrine
Antihypertensives	ACE inhibitors Chlorothiazide Hydrochlorothiazide Labetalol Mercurial diuretics Methyldopa Practolol
Antiarthritics	Aurothioglucose Colloidal gold (Europe only) Gold sodium thiomalate, thiosulfate
Anxiolytics	Lorazepam
NSAIDs	Fenclofenac Ibuprofen Naproxen Phenylbutazone
Oral hypoglycemic agents	Chlorpropamide Tolazamide Tolbutamide
Uricosuric agents	Allopurinol
Miscellaneous drugs	Iodides Penicillamine Quinidine sulfate
Chemicals; dental restorative materials	Substituted paraphenylenediamines used in color film developers; dental casting alloys and amalgam restorations

Discoid lupus erythematosus

- Chronic, scarring, atrophy producing, photosensitive dermatosis. Well demarcated cutaneous lesions.

- Etiology- unknown
  - Heat shock protein is produced in keratinocyte following UV light exposure or stress
  - This protein acts as target for T-cell mediated epidermal cell cytotoxicity.

SUMANDEEP VIDYAPEETH
K M SHAH DENTAL COLLEGE AND HOSPITAL

- 3rd- 4th decade
- Woman
- Sites- face, chest, back & extremities
- Elevated, red macule often covered by gray or yellow scale & follicular plugging
- Increase in size by peripheral growth
- Lesion may form butterfly rash over cheek & nose (malar rash)
- Can transform to Epidermoid carcinoma & less commonly basal cell carcinoma

- Common site- lips, buccal mucosa, palate & tongue
- Oral lesion begins as erythematous areas
- Sometimes slightly elevated often depressed
- Without induration with white spots
- Margin not sharply demarcated but show formation of narrow zone of keratinization

Histopathological findings

- Hyperkeratosis with keratotic plug
- Atrophy of rete pegs
- Deep inflammatory infiltrate
- Edema in lamina propria
- Thick patchy basement membrane or continuous PAS-positive juxtaepithelial deposits.

SUMANDEEP VIDYAPEETH
K M SHAH DENTAL COLLEGE AND HOSPITAL

Direct immunoflourescence

- Presence of IgG, IgM, IgA & C3 at epidermal- dermal junction or basement membrane zone

- In DLE- particulate pattern (speckled)

SUMANDEEP VIDYAPEETH
K M SHAH DENTAL COLLEGE AND HOSPITAL

Lab. Findings-

- LE cell inclusion- SLE

  Rarely in DLE

- Antinuclear antibodies-
  - Anti-DNA, anti Smith antibodies are pathognomonic of SLE

SUMANDEEP VIDYAPEETH
K M SHAH DENTAL COLLEGE AND HOSPITAL

Differential diagnosis

- Lichen planus,
- Leukoplakia,

SUMANDEEP VIDYAPEETH
K M SHAH DENTAL COLLEGE AND HOSPITAL

Treatment :

Topical steroids-

Potent topical-

- **Fluticazone propionate- 0.05%**
- **Clobetasol propionate- 0.05%**
- **Betamethasone dipropionate- 0.05%**
- **Hydrocortisone - 1%**

SUMANDEEP VIDYAPEETH
K M SHAH DENTAL COLLEGE AND HOSPITAL

Evidence

Authors	Jessop S, Whitelaw DA, Delamere FM.
Title	Drugs for discoid lupus erythematosus.
Aim	To assess the effects of drugs for discoid lupus erythematosus.
Results	Clearing or excellent improvement was seen (27%) fluocinonide use and in 10% of those using hydrocortisone, giving a 17% absolute benefit in favour of fluocinonide clearing of erythema found to be better in the hydroxychloroquine group compared to acitretin
Interpretation	Fluocinonide cream may be more effective than hydrocortisone in treating people with discoid lupus erythematosus. Hydroxychloroquine and acitretin appear to be of equal efficacy, although adverse effects are more frequent and more severe with acitretin. There is not enough reliable evidence about other drugs used to treat discoid lupus erythematosus.

Cochrane Database Syst Rev. 2017 May 5;5:CD002954

SUMANDEEP VIDYAPEETH
K M SHAH DENTAL COLLEGE AND HOSPITAL

OTHERS

BENIGN MIGRATORY GLOSSITIS

Synonym :

- Geographic tongue,
- Erythema areata migrans,
- Stomatitis areata migrans
- Wandering rash of tongue

SUMANDEEP VIDYAPEETH
K M SHAH DENTAL COLLEGE AND HOSPITAL

Clinical features

- Annular, circinate, or serpiginous lesions of the tongue with slightly depressed atrophic centers and raised white borders

WHITE SPONGE NEVUS (WSN)

SUMANDEEP VIDYAPEETH
K M SHAH DENTAL COLLEGE AND HOSPITAL

Synonyms-

- Familial white folded dysplasia of mucous membrane
- White folded gingivostomatitis
- Oral epithelial nevus
- Congenital leukokeratosis
- Cannon's disease

- **Site :**
  - **Nonkeratinized mucosa -The buccal mucosa (Bilateral)**
  - **Can be seen- palate, gingiva, floor of mouth, tongue, labial mucosa**
  - **Less frequently - esophagus, genitalia, rectum**

Clinical features :

- **Bilaterally symmetric white, soft, "spongy", or velvety thick plaques**
- **Irregular surface with fissures**

SUMANDEEP VIDYAPEETH
K M SHAH DENTAL COLLEGE AND HOSPITAL

- Mucosa appears thickened & folded
- Peculiar white opalescent hue
- Usually asymptomatic
- If involves esophagus- causes dysphagia

CHEMICAL INJURIES OF THE ORAL MUCOSA

SUMANDEEP VIDYAPEETH
K M SHAH DENTAL COLLEGE AND HOSPITAL

Etiopathology :

- Caused by a variety of agents that are caustic when retained in the mouth for long periods of time, such as aspirin, silver nitrate, formocresol, hydrogen peroxide, sodium hypochlorite, dental cavity varnishes, acid etching materials etc
- Site : At the application site (On the mucobuccal fold area and gingiva)

SUMANDEEP VIDYAPEETH
K M SHAH DENTAL COLLEGE AND HOSPITAL

References:

- Martin S. Greenberg, Michael Glick. Burket's Oral Medicine: Diagnosis and Treatment. 10th ed. Hamilton: BC Decker Inc; 2003.
- Soames J V, Southam J C. Oral Pathology. 2nd ed. New York: Oxford Medical Publications; 1993.
- Brad W. Neville, Douglas D. Damm, Carl M. Allen, Jerry E. Bouquot. Oral and Maxillofacial Pathology. Philadelphia: W. B. Saunders Company;1995.
- Gary C. Coleman, John F. Nelson. Principles of Oral Diagnosis. St.Louis: Mosby-Year Book;1993.
- Joseph A. Regezi. James J. Scuibba. Richard C.K. Jordan. Oral Pathology: Clinical Pathological Correlations. 4th ed. St.Louis: Saunders;2003
- Thissen MR et,al. A systematic review of treatment modalities for primary basal cell carcinomas. Arch Dermatol. 1999;135:1177-1183
- Nabil S, Samman N. Risk factors for osteoradionecrosis after head and neck radiation: a systematic review. Triple O, 2012 Jan;113(1):54-69.
- Bourhis J et al, Effect of amifostine on survival among patients treated with radiotherapy: a meta-analysis of individual patient data. J Clin Oncol. 2011 Jun 20;29(18):2590-7. Epub 2011 May 16
- Liu Z, Huang S, Zhang D. High dose rate versus low dose rate brachytherapy for oral cancer — a meta-analysis of clinical trials. PLOS ONE 2013; 8(6): e65423
- Baujat B,Bourhis J et al. Hyperfractionated or accelerated radiotherapy for head and neck cancer Cochrane Review, 2010
- Schwartz SM et,al. Oral cancer risk in relation to sexual history and evidence of human papillomavirus infection. J Natl Cancer Inst. 1998 Nov 4;90(21):1626-36

SUMANDEEP VIDYAPEETH
K M SHAH DENTAL COLLEGE AND HOSPITAL

1. According to Cerero-Lapiedra, for diagnosis of PVL which major criteria is must to be fulfilled?
   a. B
   b. E
   c. D
   d. A
2. The immune cell invloved in the pathogenesis of OLP is:
   a. CD8+ T-cell
   b. CD4+ T-cell
   c. Both
   d. None
3. _____ is the first line of therapy for OLP
   1. Topical steroids
   2. Systemic steroids
   3. Tacrolimus
   4. Retinoids

4. Butterfly rash is seen in
   a. Discoid lupus erythmatosus
   b. Oral Lichen Planus
   c. White spongy nevus
   d. Georaphic tongue

5. White spongy nevus is
   1. Immune mediated
   2. Habit associated
   3. Hereditary condition
   4. Candidal infection

SUMANDEEP VIDYAPEETH
K M SHAH DENTAL COLLEGE AND HOSPITAL

THANK YOU